







CASE REPORT

Abdominal epilepsy in patient of schizophrenia: A diagnostic dilemma

Javed Ather Siddiqui¹, Shazia Farheen Qureshi¹, Fatma Rabeh Ibrahim Ayari¹,
Yousef Bin Ahmed Shawosh¹

¹Mental Health Hospital, Department of Psychiatry, Taif - Saudi Arabia

ABSTRACT

Abdominal epilepsy is a rare and uncommon cause of recurrent abdominal pain. It is commonly occurring in children, but rarely in adolescents and elderly. Paroxysmal episodes of abdominal pain with neurological symptoms like dizziness, lethargy, and abnormal electroencephalogram and remarkable response to anticonvulsants confirms the diagnosis. Here we present a case of schizophrenia, who has reported with recurrent abdominal pain for 6 months, and she responded with valproic acid and remained symptoms free.

Keywords: Abdominal epilepsy, abdominal pain, schizophrenia

INTRODUCTION

Abdominal epilepsy is defined as an unexplained, paroxysmal gastrointestinal symptom such as abdominal pain, nausea, vomiting, bloating and diarrhea associated with symptoms of central nervous system such as dizziness, and lethargy (1,2). Abnormal electroencephalography findings are specific characteristic for a seizure disorder (3); and improvement of symptoms with anticonvulsant therapy is characteristic feature of abdominal epilepsy (4). Abdominal epilepsy also called autonomic epilepsy. Abdominal pain is a non-specific relatively an uncommon symptom, and it can be overlooked or under diagnosed. It presents unexplained paroxysmal symptoms associated with abdominal pathology that result from seizure activity (5). Abdominal pain may be considered as functional and be one of the common causes for clinical referrals (6). Abdominal epilepsy can be masked or misdiagnosed as a physical or

psychological disorder (7,8). Making a diagnosis for abdominal epilepsy can be very challenging for psychiatrist; some patients with abdominal epilepsy has been considered to have psychogenic abdominal pain and treated without improvement (9).

CASE

A 42-years old Saudi female patient was admitted at our chronic rehabilitation ward for 15 years. She was diagnosed case of schizophrenia, at the age of 25 years for her disturbed behavior such as suspiciousness, hearing voices, anger outburst, and irrelevant talk. She was on multiple antipsychotics, such as haloperidol, risperidone, amisulpride but was stable on olanzapine 10 mg per day last 4 years. She had a history of epilepsy, at the age of 20 years, but now for past 5 years she is seizure free. Patient presented with history of recurrent episode of abdominal pain located at epigastric region since 6 months. It is a gradual onset, burning in nature, not radiating, and it

How to cite this article: Siddiqui JA, Qureshi SF, Ibrahim Ayari FR, Shawosh YA. Abdominal epilepsy in patient of schizophrenia: A diagnostic dilemma. *Dusunen Adam The Journal of Psychiatry and Neurological Sciences* 2021;34:216-218.

Correspondence: Javed Ather Siddiqui, Mental Health Hospital, Department of Psychiatry, Taif - Saudi Arabia

E-mail: javedsiddiqui2000@gmail.com

Received: December 27, 2020; **Revised:** January 04, 2021; **Accepted:** April 06, 2021

lasts around 20-30 minutes. The pain is neither associated with any food intake nor there is an aggravation. Initially she has attacks of pain once in two or three months for a few minutes. Later, the frequency, intensity, and duration of pain is increased and for the past two to three months she had several attacks of pain every day lasted 15 to 20 minutes and occurred 2 to 3 times per day. The episode is associated with nausea and vomiting followed by neurological symptoms like dizziness and lethargy, result from seizure activity. Patient shows tiredness after episodes and becomes pale, there was no loss of consciousness, and she did not experience headache. It is sudden in onset, and there is spontaneous resolution of symptoms. She had past history of generalized tonic-clonic seizure and was on tablet carbamazepine 400 mg per day but no episode of epilepsy occurs for five years.

Her general and local examination of abdomen and nervous system did not reveal any abnormality. There is history of delayed developmental milestone and no history of epilepsy in her family. There was no history of febrile convulsions, or head injuries, hypertension, diabetes mellitus, and ischemic heart disease. She was diagnosed with gastro-esophageal reflux disease and was put on antispasmodics and proton pump inhibitors, but patient did not report any significant improvement in her symptoms. Her blood examination such as complete blood cell count, liver, and kidney function test, serum electrolytes, and stool examination for ova and parasite were within normal limit. Ultrasound abdomen was done it shows unremarkable findings. Currently, on mental status examination no active psychosis was seen, but whenever she had abdominal pain attack, her psychiatric symptoms exacerbate such as irritability, muttering to self, marked apathy, blunting of emotional responses that resulted in social withdrawal. She was maintained with olanzapine 10 mg per day and was free of psychotic symptoms.

Patient was referred to gastroenterology consultation, upper gastrointestinal endoscopy was normal and patient was referred back to our hospital. We took second opinion of neurology consultation. Computerized tomography of brain shows no abnormality; normal parenchyma, normal ventricular system, normal bony structure, and no space occupying lesions were seen. Electroencephalogram revealed an abnormality such as repetitive sharp waves discharge at right temporal leads with slow activity depicted in Figure 1, which suggestive of an epileptogenic focus. She was diagnosed with abdominal epilepsy and she was added to valproic acid 1000 mg twice per day with marked improvement of her symptoms and no more attacks occurred.

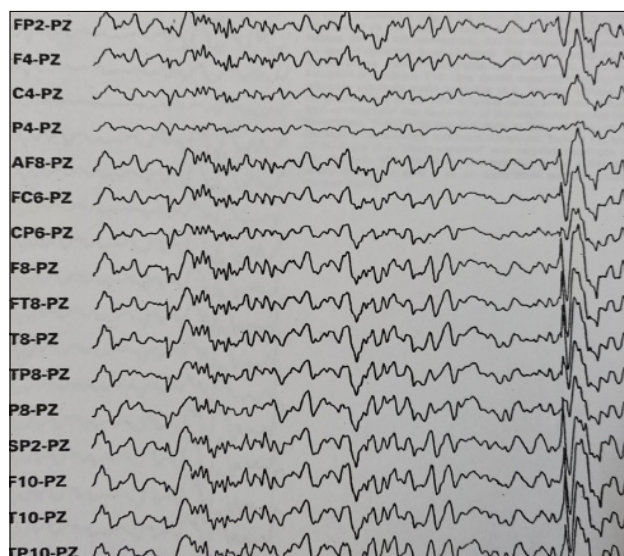


Figure 1. Electroencephalogram showing sharp waves at right temporal region with slow activity.

DISCUSSION

Recurrent abdominal pain may always become a diagnostic problem so that detailed history and careful examination may give useful clue towards etiology, to evaluate a case for recurrent abdominal pain. Due to distinct presentations, abdominal epilepsy can be either masked or misdiagnosed as a physical or psychological disorder. In our case, it is a diagnostic dilemma initially she was diagnosed gastro-esophageal reflux disease and later psychogenic abdominal pain but clinical history, abnormal electroencephalogram findings and consultation of neurology revealed abdominal epilepsy.

The pathophysiology and etiologies of abdominal epilepsy is not known but some possible causes have been described in literature, such as febrile seizures, cerebral tumors in temporal area, malformations, prematurity, bilateral perisylvian polymicrogyria, and neuroendocrine dysfunction. Another cause of abdominal epilepsy is disturbed or abnormal brain activity that arising from temporal lobe which involves the amygdala. The hypothalamus is also considered activating sympathetic pathways from amygdala to gastrointestinal tract that induce gastrointestinal symptoms. International League against Epilepsy suggested that abdominal epilepsy is considered as a part of simple or complex partial seizures (10). The association between epilepsy and psychosis came into attention since nineteenth century and comorbid psychiatric disorders are particularly common in temporal lobe epilepsy or complex partial seizure whose occurrence cannot be directly linked to the ictus (11). In recent study it is said that epileptic pain such as abdominal pain is a rare symptom of seizures in both

children and adults but it is commonly reported in children and rarely seen in adult.

Even though it commonly occurs in children, our patient is adolescent and we diagnosed her abdominal epilepsy, so it is rare condition. Our patient fulfills the diagnostic criteria of abdominal epilepsy such as pain is abrupt in onset with relatively short duration of episode, pain is commonly epigastric and it is not radiating to other body parts. Recurrent paroxysmal gastrointestinal symptoms such as abdominal pain, nausea, and vomiting are associated with symptoms of central nervous symptoms like dizziness and lethargy, and abnormal electroencephalogram showing epileptic discharge. There was also a positive response to anticonvulsant treatment with carbamazepine and valproic acid and thus our patient fulfilled all the criteria for the diagnosis of abdominal epilepsy.

Abdominal epilepsy is rare condition and easily treatable cause of paroxysmal abdominal pain. Even though it is a diagnostic dilemma proper history and careful physical examination along with unexplained, paroxysmal gastrointestinal symptoms associated with symptoms of central nervous system disturbance, abnormal electroencephalogram with finding specific for seizure disorder and improvement with anticonvulsant medication can guide us towards a definitive diagnosis.

Contribution Categories		Author Initials
Category 1	Concept/Design	J.A.S., S.F.Q.
	Literature review	Y.B.A.S., J.A.S.
	Data analysis/Interpretation	F.R.I.A., S.F.Q.
	Case follow-up (if applicable)	S.F.Q., J.A.S.
Category 2	Drafting manuscript	J.A.S., S.F.Q.
	Critical revision of manuscript	Y.B.A.S., F.R.I.A.
Category 3	Final approval and accountability	F.R.I.A., Y.B.A.S.
Other	Technical or material support	J.A.S., S.F.Q.
	Supervision	Y.B.A.S., F.R.I.A.

Informed Consent: Written informed consent was obtained from the patient.

Peer-review: Externally peer-reviewed.

Conflict of Interest: None declared.

Financial Disclosure: No financial support has been received from any institution or person for this study.

REFERENCES

- Dutta SR, Hazarika I, Chakravarty BP. Abdominal epilepsy, an uncommon cause of recurrent abdominal pain: A brief report. *Gut* 2007; 56:439-441. [\[CrossRef\]](#)
- Solana de Lope J, Alarcón Fernández O, Aguilar Mendoza J, Beltrán Coronel J, Barinagarrementeria F, Pérez Manauta J. Abdominal epilepsy in the adult. *Rev Gastroenterol Mex* 1994; 59:297-300. [Spanish]
- Peppercorn MA, Herzog AG. The spectrum of abdominal epilepsy in adults. *Am J Gastroenterol* 1989; 84:1294-1296.
- Zinkin NT, Peppercorn MA. Abdominal epilepsy. *Best Pract Res Clin Gastroenterol* 2005; 19:263-274. [\[CrossRef\]](#)
- Franzon RC, Lopes CF, Schmutzler KM, Morais MI, Guerreiro MM. Recurrent abdominal pain: when should an epileptic seizure be suspected? *Arq Neuropsiquiatr* 2002; 60:628-30.
- Leary PM. Conversion disorder. *Hand Clin Neurol* 2013; 112:883-887. [\[CrossRef\]](#)
- Harshe DG, Harshe SD, Harshe GR, Harshe GG. Abdominal epilepsy in an adult: a diagnosis often missed. *J Clin Diagn Res* 2016; 10:VD01-VD02. [\[CrossRef\]](#)
- Magon P. Abdominal epilepsy misdiagnosed as peptic ulcer pain. *Indian J Pediatr* 2010; 77:916. [\[CrossRef\]](#)
- Singhi PD, Kaur S. Abdominal epilepsy misdiagnosed as psychogenic pain. *Postgrad Med J* 1988; 64:281-282. [\[CrossRef\]](#)
- Benbadis SR. Epileptic seizures and syndromes. *Neurol Clin* 2001; 19:251-270. [\[CrossRef\]](#)
- Qureshi SF, Siddiqui JA, Ayari Ibrahim FR. Interictal psychosis – a case of psychosis of epilepsy. *Psychiatry Behav Sci* 2020; 10:161-163. [\[CrossRef\]](#)