

The Treatment Of Craniofacial Meningioma: A case report *

İsmail ERMİŞ**, Atilla ARINCI**, İlhan ELMACI***, Tahir HAYIRLIOĞLU**, Zeki ORAL***

ÖZET

Yaygın kraniyofasiyal meninjioması olan 62 yaşındaki bir bayan hasta tek seansta transkraniyal ve transfasial kombine cerrahi girişimlerle tedavi edilmiştir. Bu yazıda, tümörün çıkarılmasında uygulanan teknik tanımlanmakta ve mevcut literatür gözden geçirilmektedir.

Anahtar kelimeler: Meningioma, kraniyofasiyal cerrahi, kafa tabanı tümörleri

Düşünen Adam; 1995, 8 (2): 61-64

SUMMARY

A 62 year-old woman with an extensive craniofacial meningioma was surgically treated performing combined transfacial and transcranial approaches in one stage. In this paper, the technique used for the removal of the tumor is described and the pertinent literature is reviewed.

Key words: Meningioma, craniofacial sugery, cranial base tumors

INTRODUCTION

Meningiomas constitute the major group of mesodermal brain tumors in the current classification. As these tumors originate mainly from dura, common sites of occurrence in the anterior skull base are the olfactory grooves, tuberculum sellae, planum sphenoidale, orbital roof, optic sheath and sphenoid wings. Larger tumors can involve multiple sites.

The operative strategy depends upon the site of origin, extent, predominant growth direction and biologic behavior. The intraosseous meningiomas that spread over large area of the skull base merit special consideration (13). There are publications primarily

focusing on meningiomas arising mainly in extracranial structures such as scalp, temporal bone, pterygopalatine fossa, nose, orbit and paranasal sinuses (4,5,7,10-12,15-17).

The term craniofacial meningiomas refersto a group of craniofacial tumors involving the anterior skull base and expanding into the orbits and paranasal sinuses. Craniofacial tumors are divided into three major groups:

- (a) primary tumors of the paranasal sinuses that expand intraorbitally and intracranially;
- (b) tumors arising from the skin or appendages (lacrimial gland) and expanding into the orbit and anterior cranial fossa and

* Presented at the 16th Congress of Turkish Plastic and Reconstructive Surgery, Ankara, October 1-4, 1994.

** İst. Univ., School of Medicine, Department of Plastic and Reconstructive Surgery, İstanbul.

*** Bakırköy Mental Hospital, Department of Neurosurgery, İstanbul

(c) primary intracranial tumors that originate within the cranium and expand extracranially into the orbit and paranasal sinuses. Craniofacial meningiomas fall into this last category (6). In this paper, we present the surgical treatment of a case with such a craniofacial meningioma.

CASE

Ş.E., a 62 year-old woman was consulted for a massive and extensive lesion on her left craniofacial area. She previously had undergone partial resection of the mass through a temporo-frontal skin incision and it was revealed to be a meningioma (Figure 1). Computed tomography scan showed the lesion to be intra- and extracranial mass, extending from the right temporal and frontal bone over the entire orbital and ethmoidal roof, frontal sinus and through a big portion of the maxilla (Figure 2).

General anesthesia with oral endotracheal intubation was used. The operation consisted of two stages: transcranial (intracranial) and transfacial. These stages were accomplished in one step. Transcranial stage started with a coronal scalp incision, followed by a hemifrontal osteoplastic craniotomy to approach to the intracranial part of the lesion since the

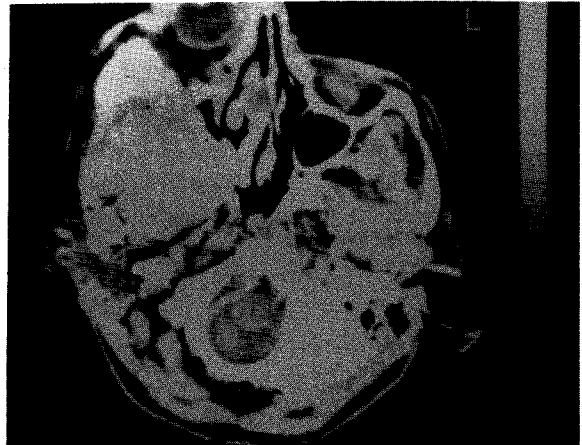


Figure 2. CT scan showing the intra- and extracranial involvement of the craniofacial skeleton.

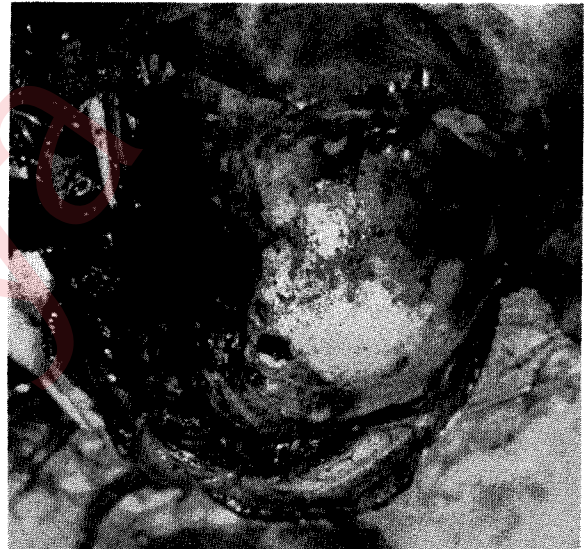

Figure 3. The per-operative photograph of the patient prior the transcranial resection of the cranial involvement.

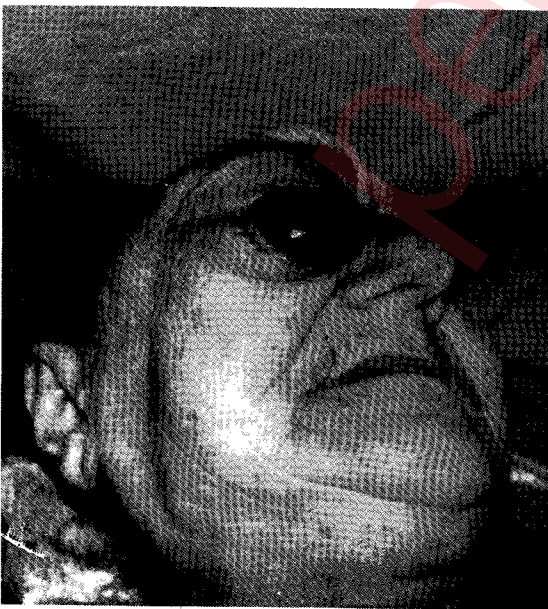

Figure 1. The patient seen with intra- and extracranial (craniofacial) meningioma involving the right lateral side with proptosis of the globe.

other half of the frontal bone was invaded by the tumor (Figure 3). Following removal of the invaded part of the frontal bone and intracranial part of the lesion, the resection of the orbital and ethmoidal roofs, ipsilateral frontal sinus, ethmoidal sinus, fossa sphenoplatina and subtemporalis resection was performed. Bleeding from the bony edges was controlled with bone wax. Transfacial stage started through a Weber-Ferguson incision with extension to the eyelids and a cheek flap was elevated. Resection of the maxilla including the dento-alveolar segment and exenteration of the globe was accomplished.




Figure 4. The patient seen following craniofacial resection of the mass.

Closure of the defect between the anterior cranial fossa and the facial structures was performed by utilization of a galeal frontalis myofascial flap. It was difficult to determine the borders of the tumor during surgery and the lesion had produced an extensive local destruction. The post-operative period was uneventful and there was not cerebrospinal fluid leakage (Figure 4). The patient was followed up for one year post-operatively and recurrences were noted in some parts of the craniofacial skeleton, but no effort was made to reoperate her at that stage.

DISCUSSION

Meningiomas tend to grow slowly and except the sarcomatous form, the lesion is clinically and biologically benign. Unless all of the tumor is removed during the initial operation, the likelihood of recurrence is extremely high. With a very extensive meningioma that is causing functional disturbances, even a palliative resection can give long-term benefit owing to the slow rate of tumor growth. With very extensive craniofacial meningiomas that are not amenable to radical excision, the surgeon should consider performing a palliative craniofacial tumor resection before the patient develops signs of ce-

rebral compression and irreversible cranial nerve damage (13).

From the surgical standpoint, it is useful to classify meningiomas of the anterior skull base into three groups;

- (a) meningiomas with predominantly intracranial growth,
- (b) meningiomas with predominantly extracranial growth and
- (c) meningiomas with intra and extracranial growth (craniofacial meningioma). A combined craniofacial approach is of great potential value for the complete removal of large meningiomas having both intra- and extracranial components (6,13).

Some authors recommend a two-stage operation for intraosseous skull base meningiomas that have spread across the midline to involve the paranasal sinuses or facial structures. In the first, intracranial part of the operation, the tumor and involved dura are resected and the defect is reconstructed with a graft. With an interval of one to three months depending on the expansion of lesions and condition of the patient, the extracranial part of the meningioma is removed with the involved skull base and the bony defect is closed with free bone grafts (2,3). Samii et al. think that the point at which an intra- or extracranial tumor component located beyond the dura can still be resected through one surgical approach is indefinite and depends on the functional importance of structures located between the intra- and extracranial tumor components and whether those structures might be more easily isolated from the opposite side.

When craniofacial resection is indicated for a very large tumor, they perform both parts of the operation in one stage, provided a complete tumor removal is feasible. Also, when there is advanced tumor infiltration of the cavernous sinus with amaurosis on one side, they advocate resection of the cavernous sinus with preservation of the internal carotid artery. In cases where the internal carotid artery has become infiltrated by tumor in its cavernous portion, a goal for future is to resect the involved arterial segment and preserve the cerebral blood supply by means of a preoperative intraextracranial microvascular anastomosis or by appropriate intraoperative

vascular surgery (13). Anand and Gabibov point out that a two-staged resection in craniofacial meningiomas may reduce operative morbidity by lessening the possibility of intracranial contamination from the nasal cavity and of CSF leakage, as well as reducing the operative time for a combined approach. However, they emphasize that the indications for staging of the procedure are indeed few (1,6).

A combined transcranial and transfacial approach is needed for adequate exposure of the intracranial and extracranial portions of the tumor to provide the best hope of a surgical cure. Another consideration that dictate a combined surgical approach in these patients is that after removal of the tumor and its extension, major reconstructive needs exists which are not only for aesthetic purposes. The large areas of dead space between the anterior cranial fossa and paranasal sinuses and pharyngeal space can lead to infectious and lethal complications. The use of a viable flap and a bone graft for reconstruction of the skull base can be performed along with facial reconstruction and minimize the risks of delayed complications (8,9,14).

As a conclusion, modifications in craniofacial resection techniques are based on the extent and nature of the underlying pathology and the optimum treatment for craniofacial meningiomas includes early diagnosis and combined craniofacial resection with immediate reconstruction.

REFERENCES

1. Anand VK, Al-Mefty O: Craniofacial resection. In: Plastic and Reconstructive Surgery of the Head and Neck, Proceed. Fifth Int Symp Stucker FJ (ed), B C Decker, Philadelphia, p 487-492, 1991.
2. Bonnal I, Thihaut A, Brotchi I: Invading meningiomas of the sphenoid ridge. *J Neurosurg* 53:587-599, 1980.
3. Derome PJ, Guiot G: Bone problems in meningiomas invading the base of skull. *Clin Neurosurg* 25:435-451, 1978.
4. Farr H, Gray G, Vrana M, Paino M: Extracranial meningioma. *J Surg Oncol* 5:411-420, 1973.
5. Gabibov G, Blinkov S, Tcherekayev VA: The management of the optic nerve meningiomas and gliomas. *J Neurosurg* 68:889-893, 1988.
6. Gabibov GA, Tcherekayev VA: The treatment of craniofacial meningiomas. *J Craniofac Surg* 1:196-199, 1990.
7. Ho K: Primary meningioma of the nasal cavity and paranasal sinuses. *Cancer* 46:1442-1447, 1980.
8. Jackson IT, Adham MN, Marsh WR: Use of the galeal frontalis myofascial flap in craniofacial surgery. *Plast Reconstr Surg* 77:905-910, 1986.
9. Jones NF, Schramm VL, Sekhar LN: Reconstruction of the cranial base following tumor resection. *Br J Plast Reconstr Surg* 40:155-162, 1987.
10. Karp L, Zimmerman L, Borit A, Spencer W: Primary intraorbital meningiomas. *Arch Ophthalmol* 91:24-28, 1974.
11. Lee K, Suh J, Lee Y, Berry Y: Meningioma of the paranasal sinuses. *Neuroradiology* 17:165-171, 1979.
12. Nager G, Heroy J, Hoepflinger M: Meningiomas invading the temporal bone with extension to the neck. *Am J Otolaryngol* 4:297-324, 1983.
13. Samii M, Draf W: Meningiomas. In: *Surgery of the Skull Base*, Samii M and Draf W (eds), Springer-Verlag, Berlin, p208-224, 1989.
14. Shapiro K: Editorial commentary. *J Craniofac Surg* 1:200, 1990.
15. Shuangshoti S, Panyathanya R: Ectopic meningiomas. *Arch Otolaryngol* 98:102-105, 1973.
16. Suzuki H, Gilbert E, Zimmerman B: Primary extracranial meningioma. *Arch Pathol* 84:202-206, 1967.
17. Whicker J, Devine K, MacCarthy C: Diagnostic and therapeutic problems in extracranial meningiomas. *Am J Surg* 126:452-457, 1973.